

ABNORMAL COLPOSCOPY BUT NORMAL HISTOLOGY OF THE UTERINE CERVIX

Professor Goran Grubišić

President of Croatian Society for Colposcopy and
Cervical Pathology, CMA

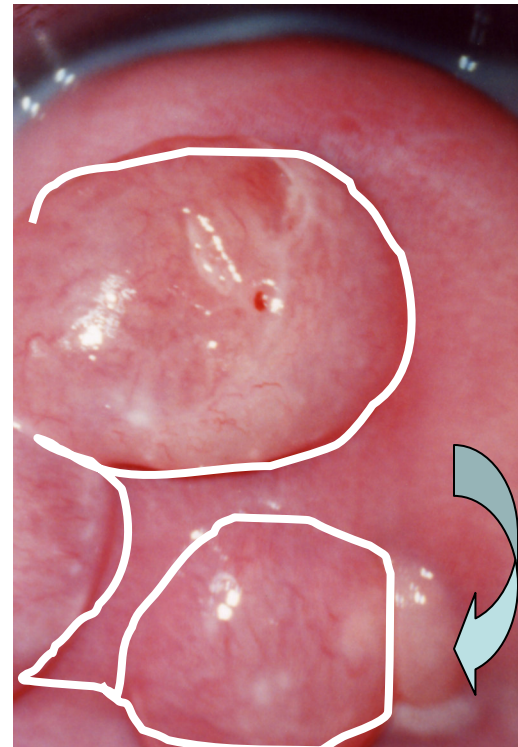
Head of OB/GYN Clinic in University Hospital *Sisters of
Charity* in Zagreb, Vinogradska 29, Croatia

www.kbsm.hr/kolposkopija
ginekologija@kbsm.hr

- According to Walter's recommendations, I present four patients (A, B, C and E) with abnormal speculoscopic and colposcopic patterns of the uterine cervix surface
- Histological findings revealed neither squamous nor cylindric epithelium abnormalities

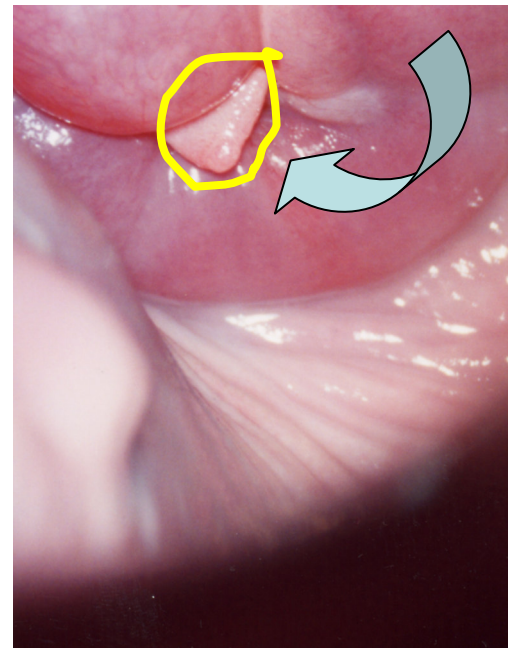
Patient A

- The anterior lip of the uterine cervix with three enlarged Nabothian cysts (***white scribble***)
- SCJ not visible (***curved left arrow***)
- Finding classified as unsatisfactory



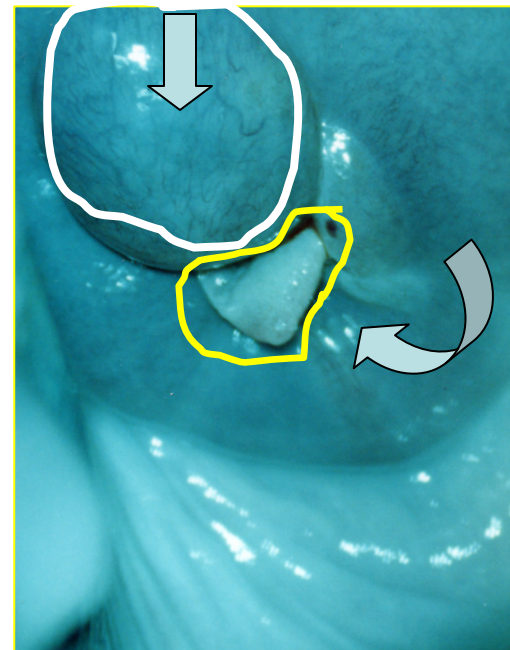
Patient A

- Projection of the external cervical orifice, SCJ not visible (*curved left arrow*), papilloma-like growth on the 12 o'clock site (*yellow scribble*)



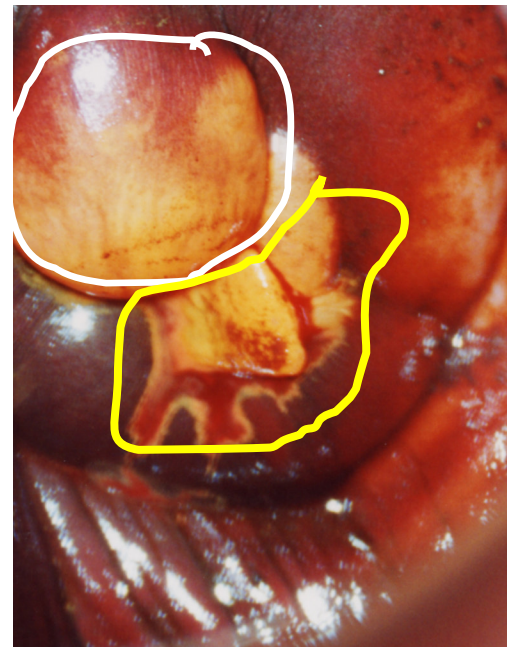
Patient A

- The anterior lip of the uterine cervix with an enlarged Nabothian cyst (**white scribble**)
- Papilloma-like growth (**yellow scribble border**)
- SCJ not visible
- Finding is unsatisfactory (**curved left arrow**)
- Capillary network regular in Kraatz green light (**down arrow**)



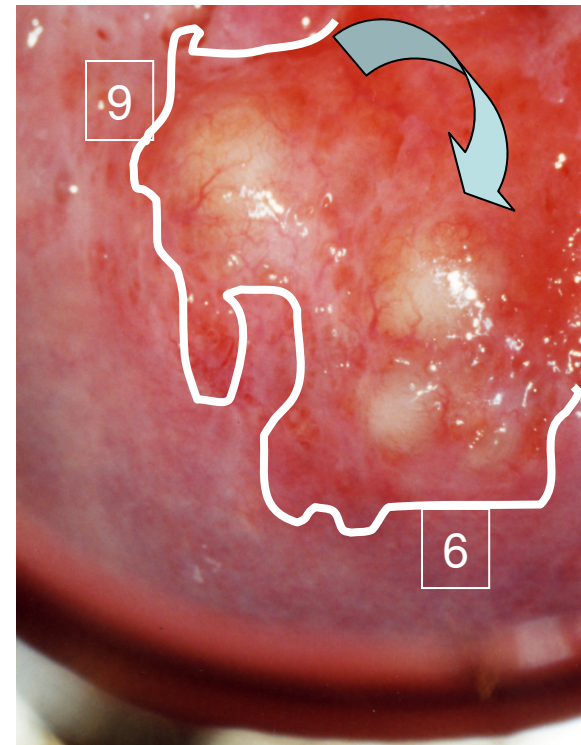
Patient A

- The anterior lip of the uterine cervix with an enlarged iodine negative Nabothian cyst surface (**white scribble**)
- SCJ not visible
- Peripheral from 2 to 6 o'clock iodine negative area (**yellow scribble**)
- Finding is unsatisfactory
- Target biopsies revealed no SIL



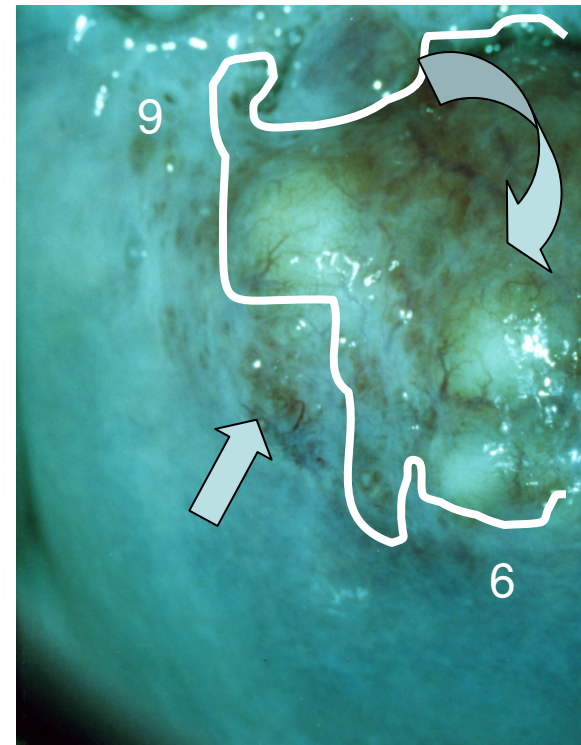
Patient B

- The posterior lip of the uterine cervix, area from 6 to 9 o'clock demonstrating visible SCJ (**white scribble**) and three Nabothian cysts (**curved left arrow**)



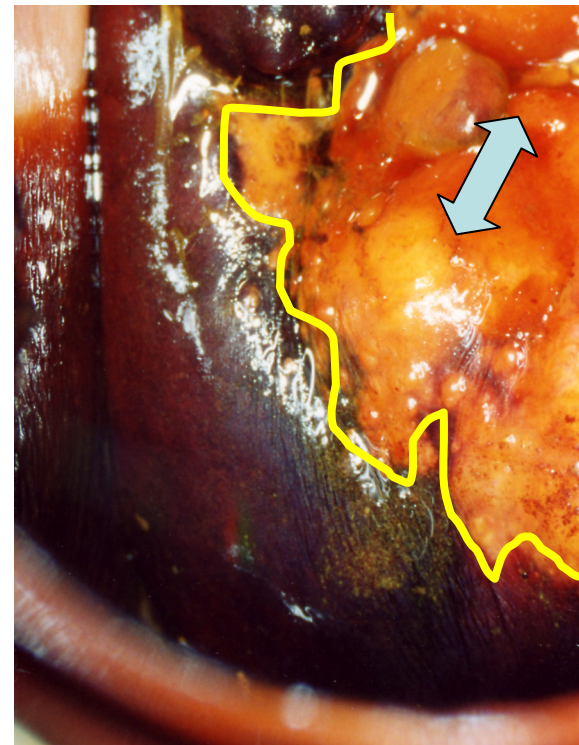
Patient B

- The posterior lip of the uterine cervix, area from 6 to 9 o'clock demonstrating visible SCJ (**white scribble**) and three Nabothian cysts (**curved left arrow**)
- Capillary network partly visible without vascular disarrangement (**up arrow**)



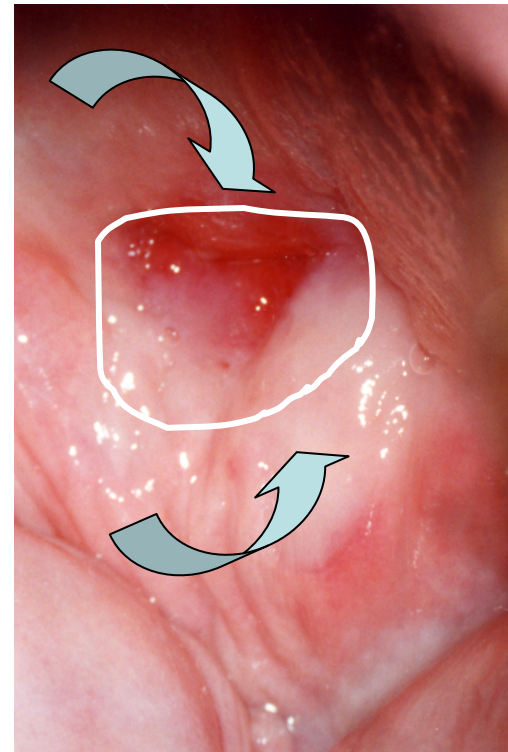
Patient B

- The posterior lip of the uterine cervix, area from 6 to 9 o'clock demonstrating visible SCJ (**yellow scribble**) and three Nabothian cysts
- Iodine captation revealed iodine negative area of Nabothian cysts surface as well as that with columnar epithelium (**up-down arrow**)
- There was no SIL on biopsy



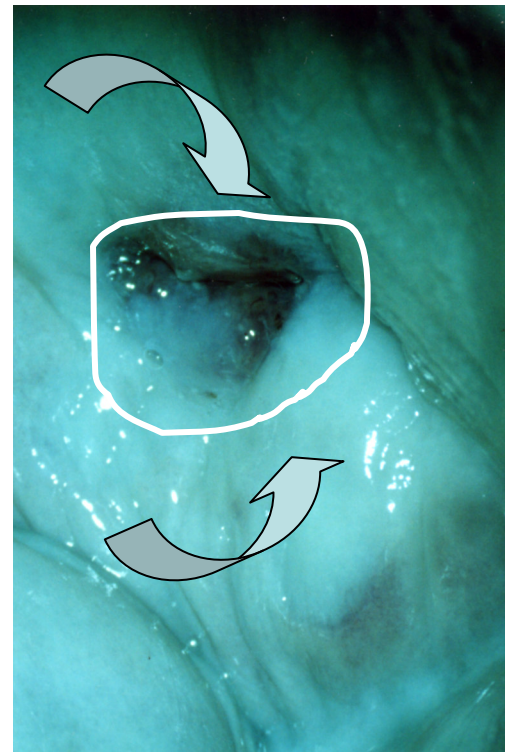
Patient C

- Uterine portio after conisation, external orifice well-visible (**curved down arrow**)
- but no SCJ (**white scribble**)
- Scars of the posterior lip (**curved up arrow**)
- Cytology reveals no SIL



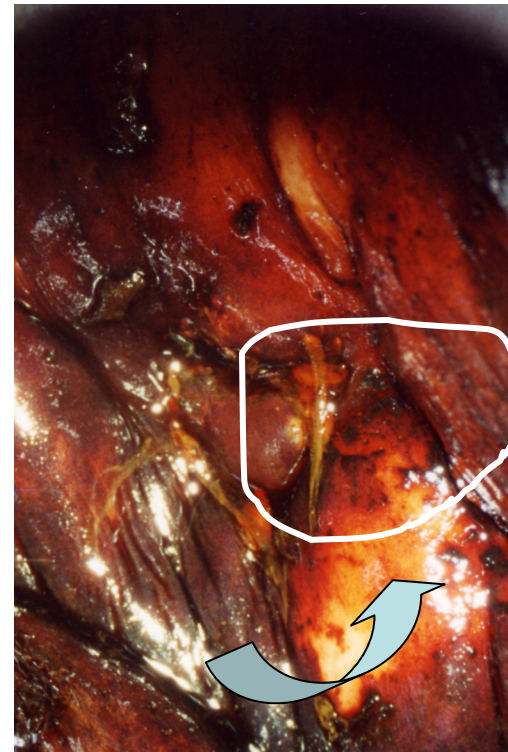Patient C

- Uterine portio after conisation, external orifice well-visible (**curved down arrow**), but no SCJ (**white scribble**)
- Scars of the posterior lip (**curved up arrow**)
- Cytology reveals no SIL



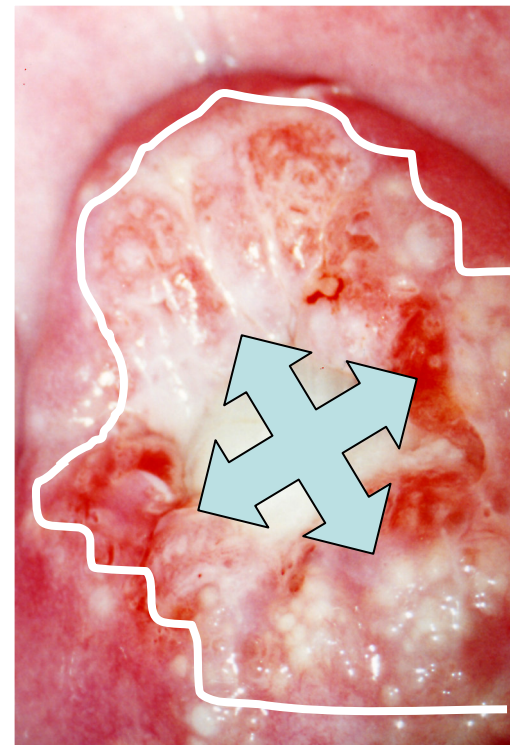
Patient C

- Uterine portio after conisation, external orifice well-visible, but no SCJ (**white scribble**)
- Scars of the posterior lip (**curved up arrow**)
- Schiller's test negative
- Cytology reveals no SIL



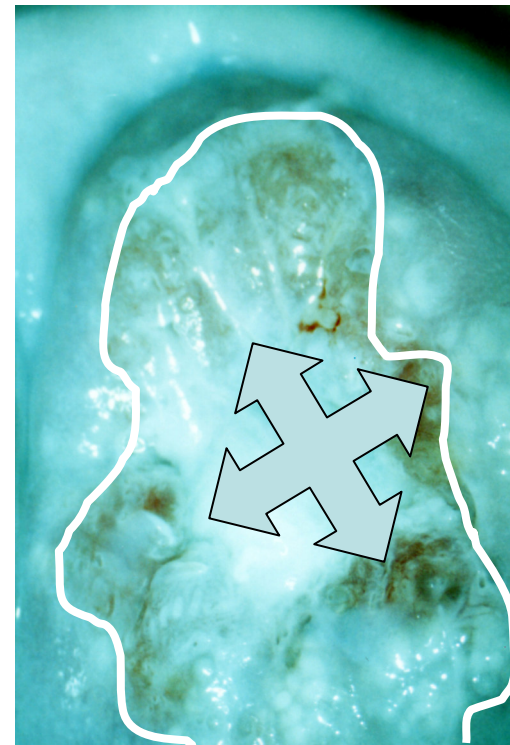Patient D

- Eversion of the cervical lips demonstrating well-visible SCJ (**white scribble**) as well as abundant inflammatory discharge from the cervical surface (**quad arrow**)
- Cytology revealed inflammation only



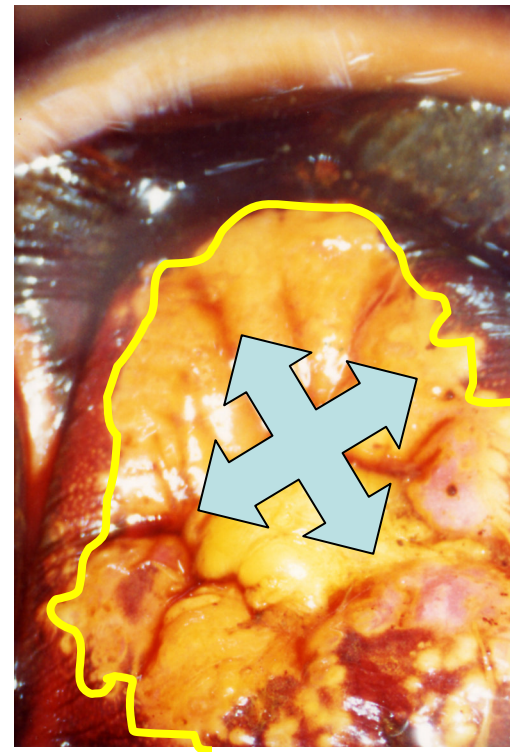
Patient D

- Eversion of the cervical lips demonstrating well-visible SCJ (**white scribble**) as well as abundant inflammatory discharge from the cervical surface (**quad arrow**)
- Cytology revealed inflammation only



Patient D

- Schiller's test demonstrated well-demarcated areas of the pluristratified and columnar epithelium *(yellow scribble)*
- In the middle of the cervical external orifice one can see abundant inflammatory mucus *(quad arrow)*



- This educational material belongs to Goran Grubišić's colpophotographic records from regular practice in the colposcopy unit and may be used in educational purposes.